

## LEVAMISOLE TOXICITY IN SHEEP: CASE STUDY

P.A. Dar<sup>1</sup>, S. A. Ahanger<sup>2</sup>, M. Mehrajudin<sup>3</sup>, M.A. Rather<sup>4</sup>, M.M. Shah<sup>5</sup>

<sup>1,3</sup>Veterinary Assistant Surgeon, Bandipora, Department of Sheep Husbandry(J&K), <sup>2</sup>DSHO-Bandipora, Department of Sheep Husbandry(J&K), <sup>4</sup>In-charge Assistant Research Officer, Kralpathri, Department of Sheep Husbandry(J&K). <sup>5</sup>Deputy Director Research, D.I.L., Department of Sheep Husbandry(J&K).

Manuscript received on 03.08.2020, accepted on 25.08.2020

### ABSTRACT

A flock comprising of fifty-five animals where dewormed with high dose of levomesole @ above 20 ml (3-4 times the normal dose) by the farmer without prior consultation of concerned veterinarian. After administration of the drug, toxicity symptoms like depression, anorexia, seizures, ataxia and frothy salivation were observed in 35 animals. Out of these 35 animals, 17 did not respond to treatment and died within five days. Line of treatment given was intravenous fluids, liver tonics and dexona which resulted in amelioration and eventual recovery of these morbid animals.

**Key words:** Levamisole, Sheep, Toxicity.

### Case history and observations

A flock comprising of about fifty-five animals was administered high dose of levomesole 6.78 % @ above 20 ml (3-4 times the normal dose) by the farmer without prescription. The flock was immediately attended by a team headed by veterinary Assistant surgeon. The team observed that about thirty-five animals were severely affected. The clinical observed were depression, anorexia, seizures, ataxia, abdominal breathing and drooling of frothy salivation. The postmortem findings observed were discoloration along with swelling of liver besides severe congestion of lungs (Fig 1 and 2). The kidneys presented petechial haemorrhages.

#### Treatment

Keeping in view the history, clinical signs and postmortem findings animals were treated with fluids, liver tonics and dexona. Despite treating

whole flock only 18 animals survived whereas 17 animals did not respond to treatment. High mortality rate of 48.57 in the present study was due to late reporting of farmer and high anthelmintic dose drenched to lambs having low body weight. However, the animals which survived were possessing good body conformation and relatively higher body weight.

#### Discussion

Levamisole is an anthelmintic of imidazothiazole class with immunostimulant property. Recommended dose rate of levamisole is 7.5 mg/kg once orally. The adverse effects of levamisole overdose are attributed to narrow therapeutic index and stimulation of nicotinic acetylcholine receptors and subsequent reduction in convulsion threshold (Rehni and Singh, 2010), and paralysis of respiratory muscles and asphyxia

(Hsu, 2008). Similar, symptoms of depression, anorexia, seizures, ataxia and frothy salivation in animals due to levamisole toxicity were also reported in dogs by Gokce *et al.*, (2015) and in adult bullocks of Red Kandhari breed by Ravindra *et al.*, (2016). However, Plum. (1999) in dogs reported pulmonary edema and allergic skin reactions and consequent death.

### Conclusion

Self-medication is usually fatal and results in heavy economic dent to farmers. Further, as there is no specific antidote for levamisole toxicity,

therefore, focus should be given on awareness among farmers regarding the adverse effects of toxicity, appropriate dose of a drug and appropriate time for deworming, besides the proper consultation of concerned veterinarian.

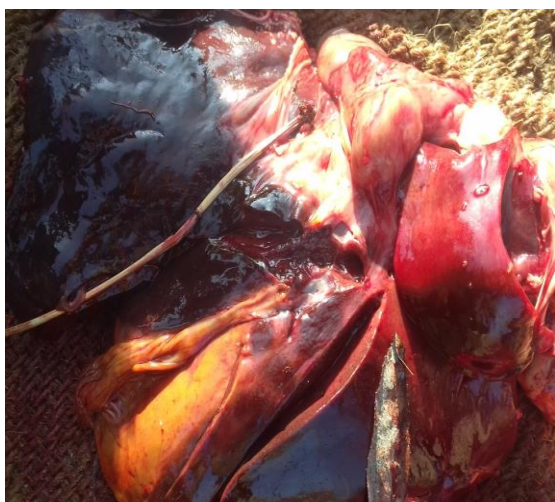


Fig- 1 Liver presenting discolourations

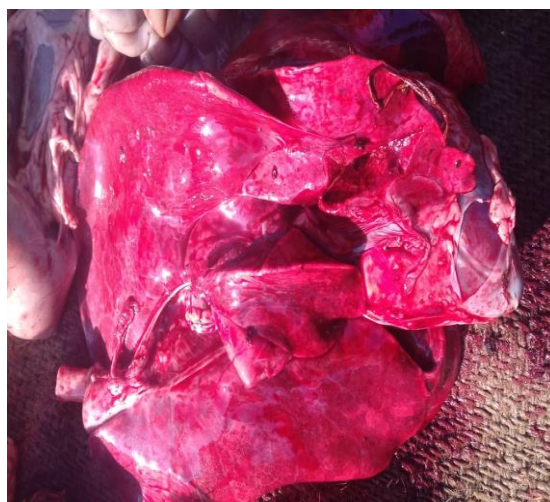

Fig-2 Lungs (Highly congested)

### References

Gokce HI., Gunes V., Erdogan HM., Cital M., Akca A., Yuksek N. (2004). The effects of levamisole poisoning on the haematological and biochemical parameters in dogs (in German). *Dtsch Tierarztl Wochenschr* **111**: 81-85.

Hsu WH., (2008). *Handbook of Veterinary Pharmacology*. 1st ed., Wiley Blackwell, Ames, pp. **150**.

Muntener CR., Bruckner L., Sture, A., Althaus FR., Caduff- Janosa P. (2010). Vigilance for veterinary Medicinal products: declarations of adverse reactions in the year 2009 (in German). *Schweizer Archiv Fur Tierheilkunde*. **152**:575-583.

Plumb DC. (1999). *Veterinary Drug Handbook*. 3rd ed., Iowa State University Press, Ames, pp. **750**.

Ravindra K., Anil UB., Ashwinin AB., Hidayat AS., Akash SJ. (2016). Acute oxyclozanide -levamisole poisoning in red kandhari bullocks. *Journal of advance veterinary research*, **7** (1): 16-17.

Rehni AK., Singh TG. (2010). Levamisole- reduction in seizure threshold: A possible role of nicotinic acetylcholine receptor-mediated pathway. *Naunyn Schmiedeberg's Archives of Pharmacology*. **382**:279-285.